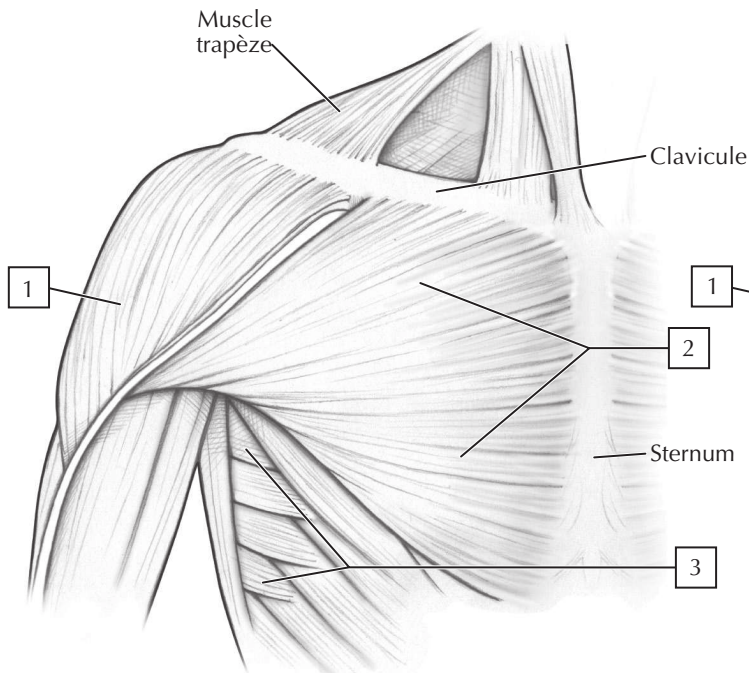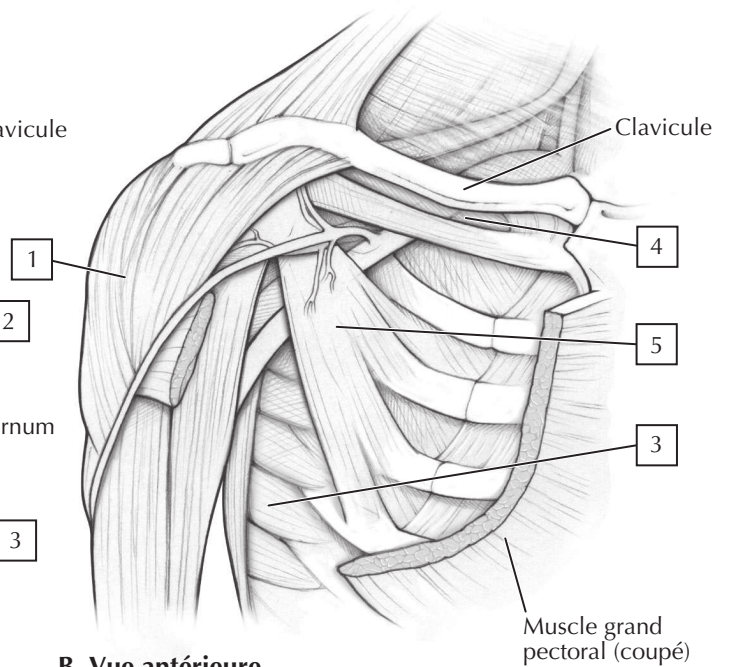
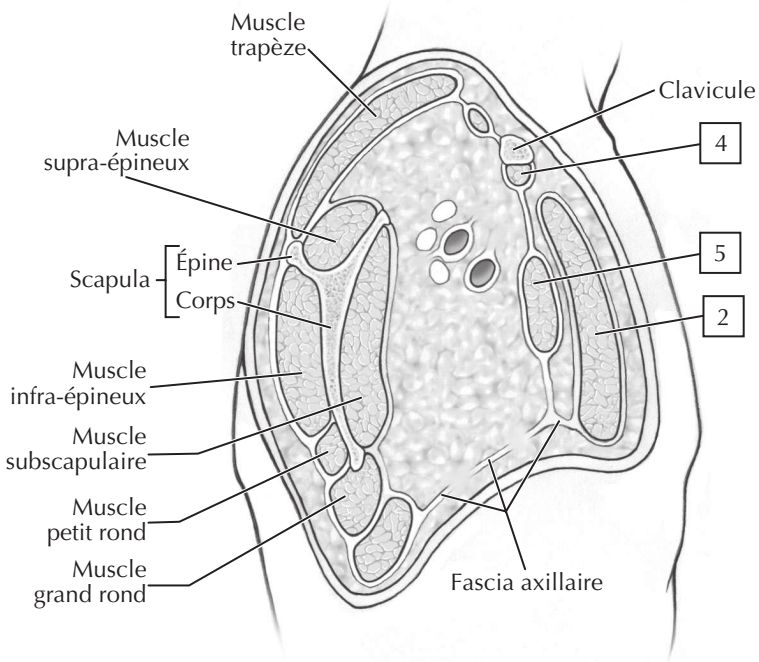


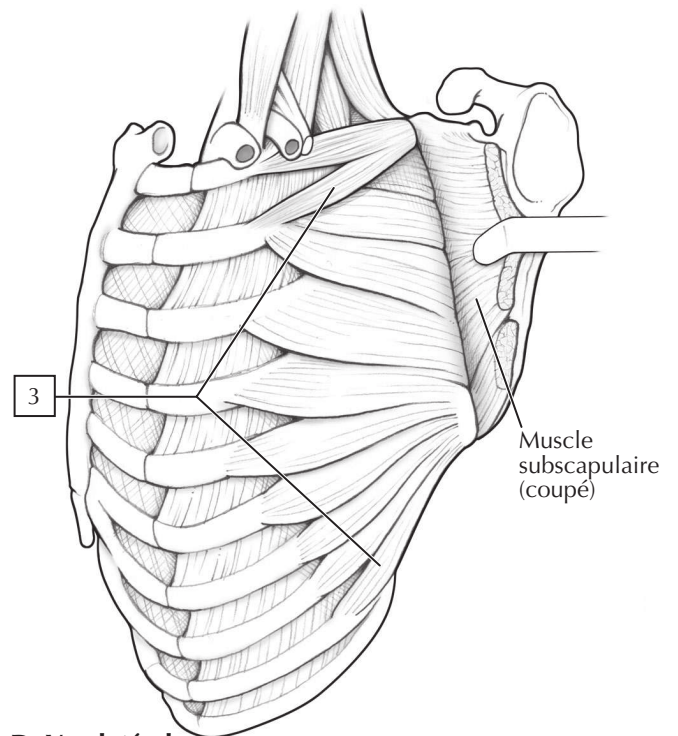
A. Vue antérieure



B. Vue antérieure



C. Coupe parasagittale oblique de la fosse axillaire



D. Vue latérale