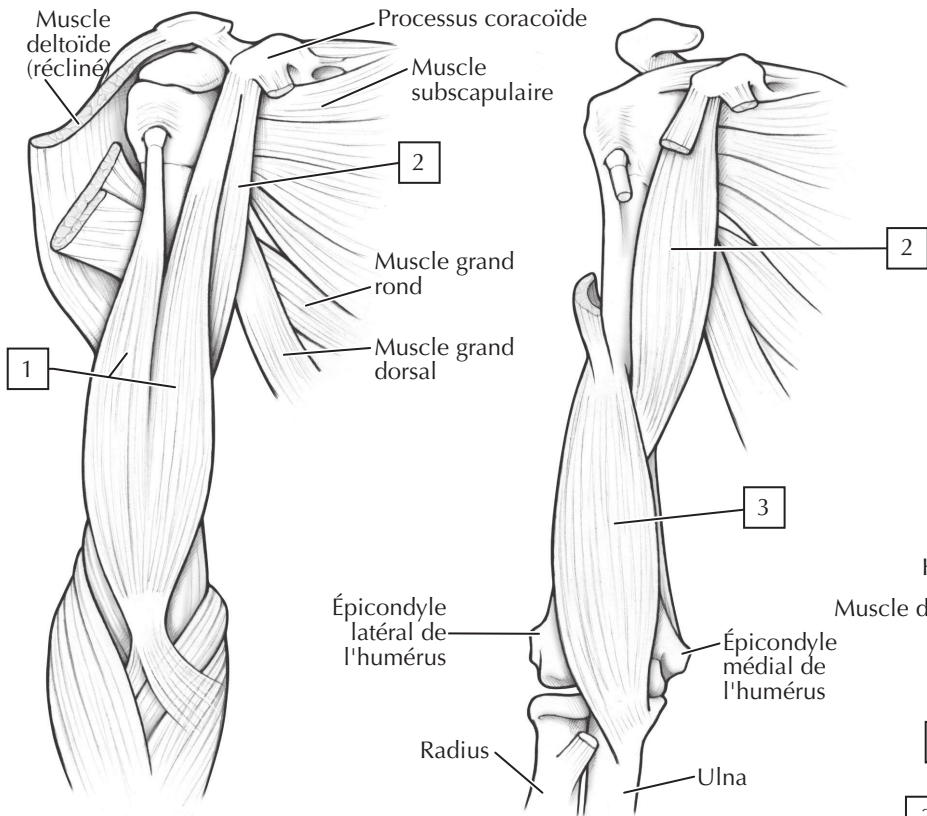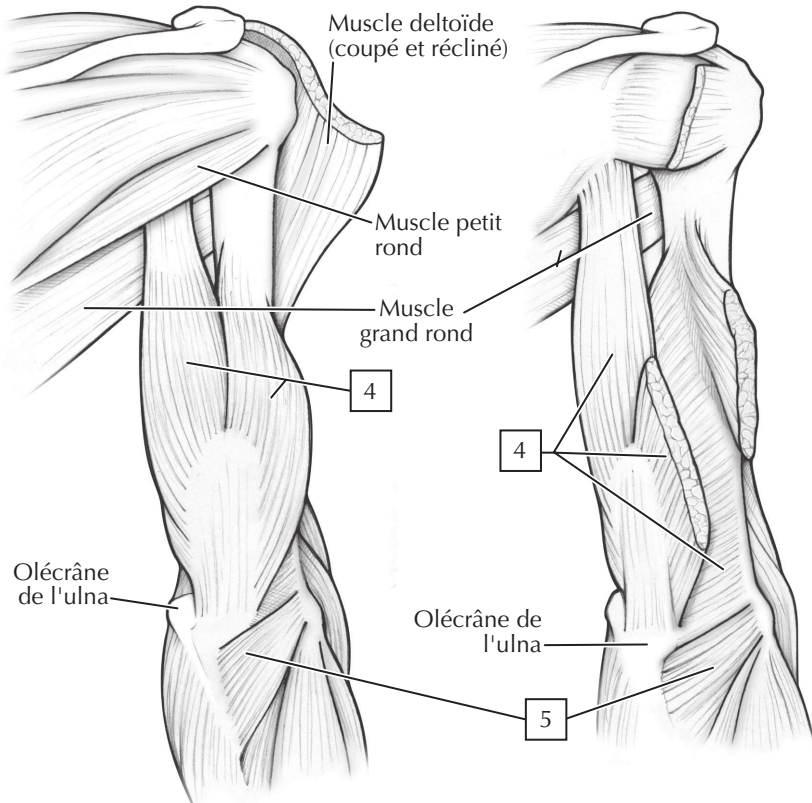


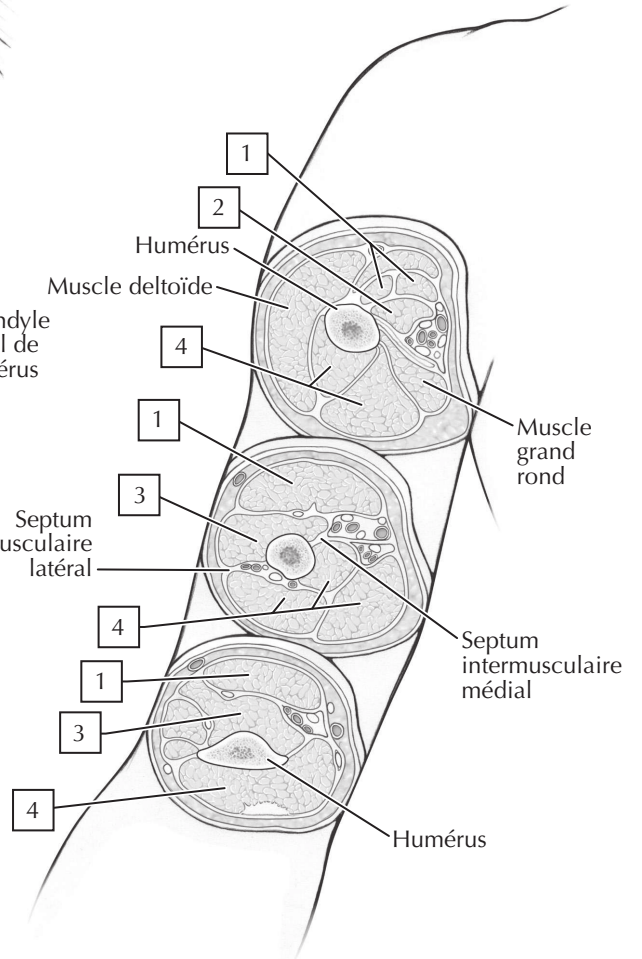
A. Plan superficiel

B. Plan profond



D. Plan superficiel

E. Plan profond



C. Coupes transversales du bras